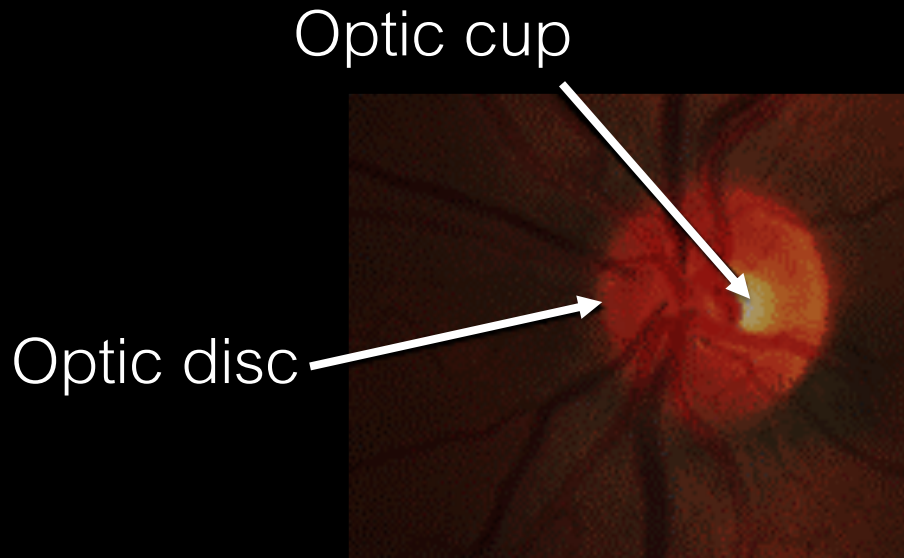


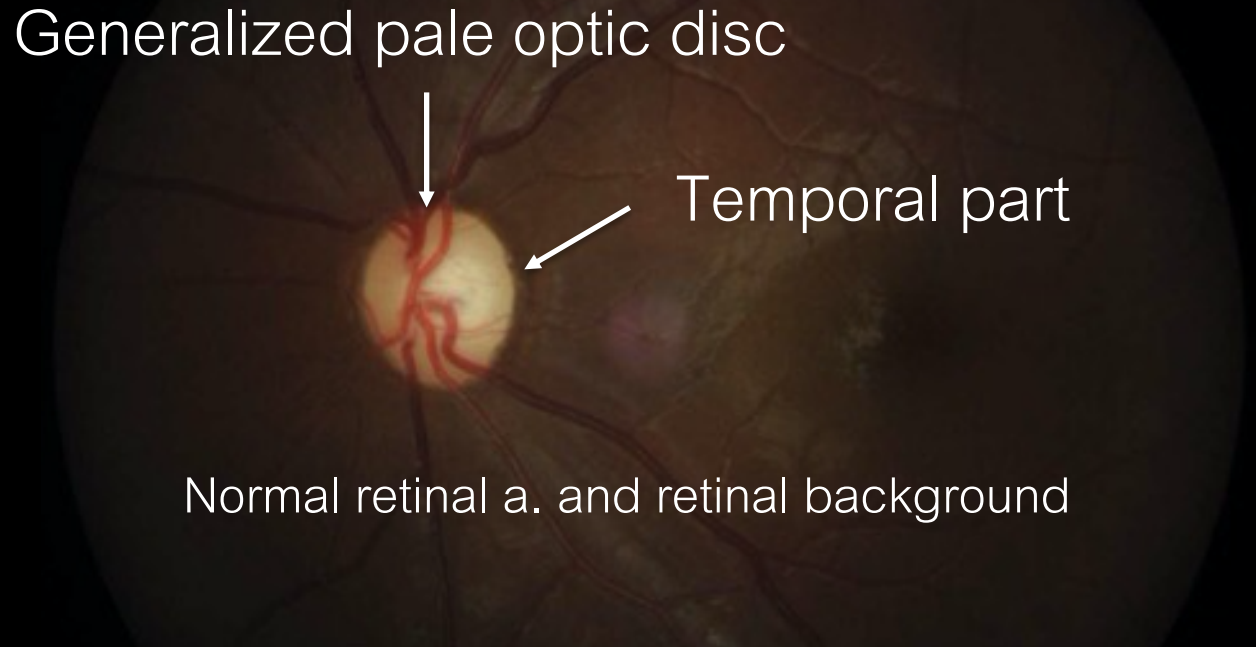
# Spot Diagnosis Case 1

## Lessons Learnt

A 20-year-old insulin-treated man with progressive visual myopia for 10 years



Normal



Bilateral optic atrophy

Fundoscopic examination



# DIDMOAD or Wolfram Syndrome

- **DI**, **DM**, **O**ptic **A**trophy, **D**eafness, and other abnormalities
- Rare AR neurodegenerative disease
- Result in death before the age of 50 years (respiratory failure)
- *WFS1* gene encodes wolframin → ER calcium homeostasis  
(transmembrane protein)
- Alterations in ER function → accumulation of misfolded protein → activation of UPR → **ER stress** in pancreatic  $\beta$  cell → DM
- Wolframin highly expressed in brain, olfactory bulb, pancreatic  $\beta$  cell, heart



## **DIDMOAD: nonautoimmune Insulin-dependent DM**

Non HLA-linked insulin-dependent DM

Average age of diagnosis: 6 years (3 weeks to 16 years)

Microvascular complications are rare and slowly progress.

Distinguish from T1D

- Earlier diagnosis
- Lower prevalence of ketoacidosis
- Less often positive autoantibodies
- Longer duration of remission
- Higher frequency of hypoglycemia (neurologic dysfunction)



## **DIDMOAD: Optic atrophy**

- Average age of diagnosis: 11 years (6 weeks to 19 years)
- Reduced in VA and loss of color vision → progression → blindness
- Average retinal thickness is significantly low
- Few case associated with any type of retinal pigmentary change
- Annual eye examination is essential

(VA, color-vision testing, fundoscopy, VF, optic coherence tomography scan)

- No medical treatment



## **DIDMOAD: deafness**

- Average age of diagnosis : 12 years
- Sensorineural hearing loss (high frequency)
- Treatment: hearing aid/cochlear implant

## **DIDMOAD: diabetes insipidus**

- Average age of diagnosis : 14 years (3 months to 40 years)
- Partial central DI
- Treatment: Intranasal or oral desmopressin



# DIDMOAD or Wolfram Syndrome

Currently, no effective treatment

Early diagnosis leads

- Proper prognostication
- Prevent complications
- Genetic counseling

## Take home message

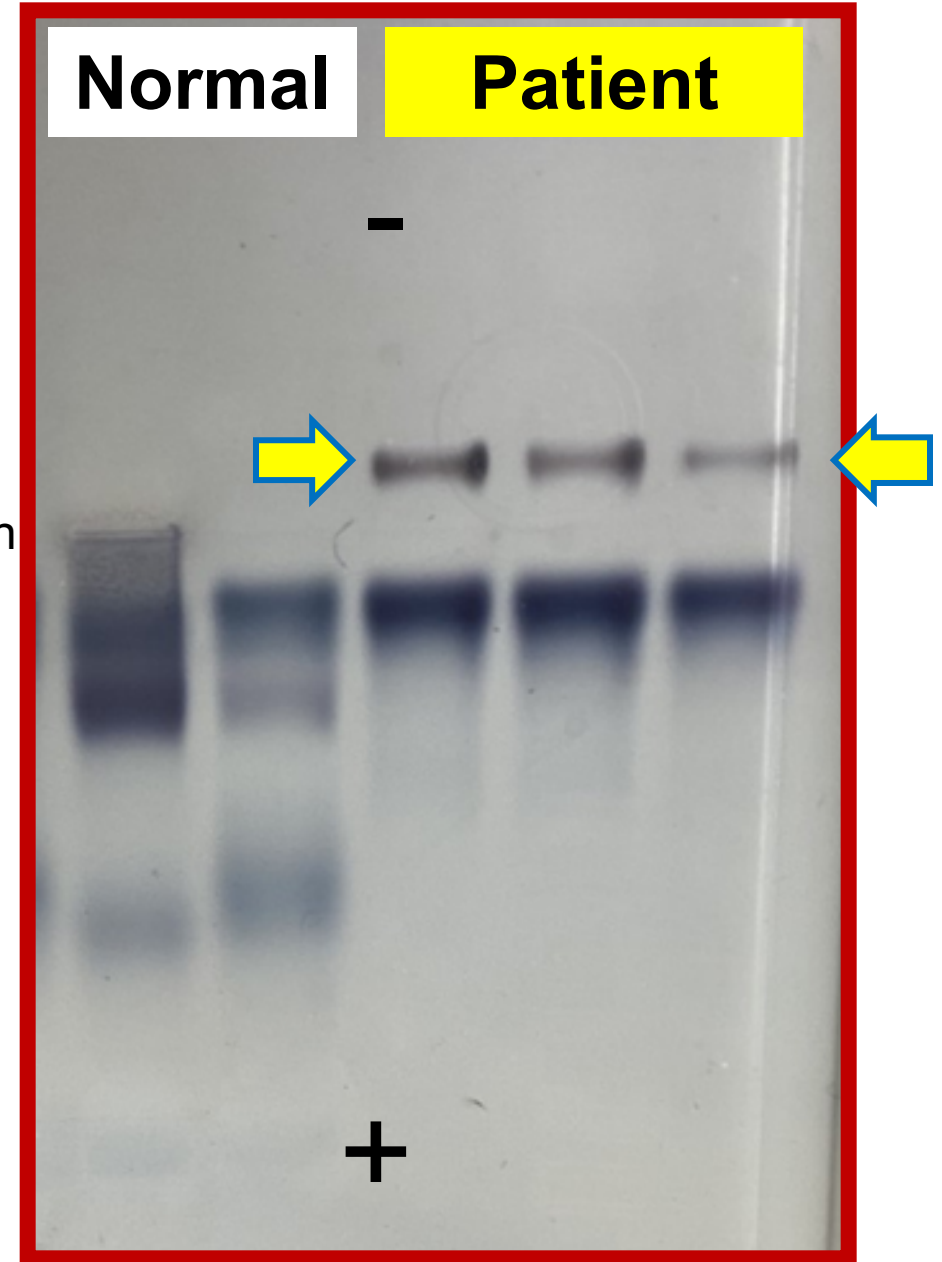
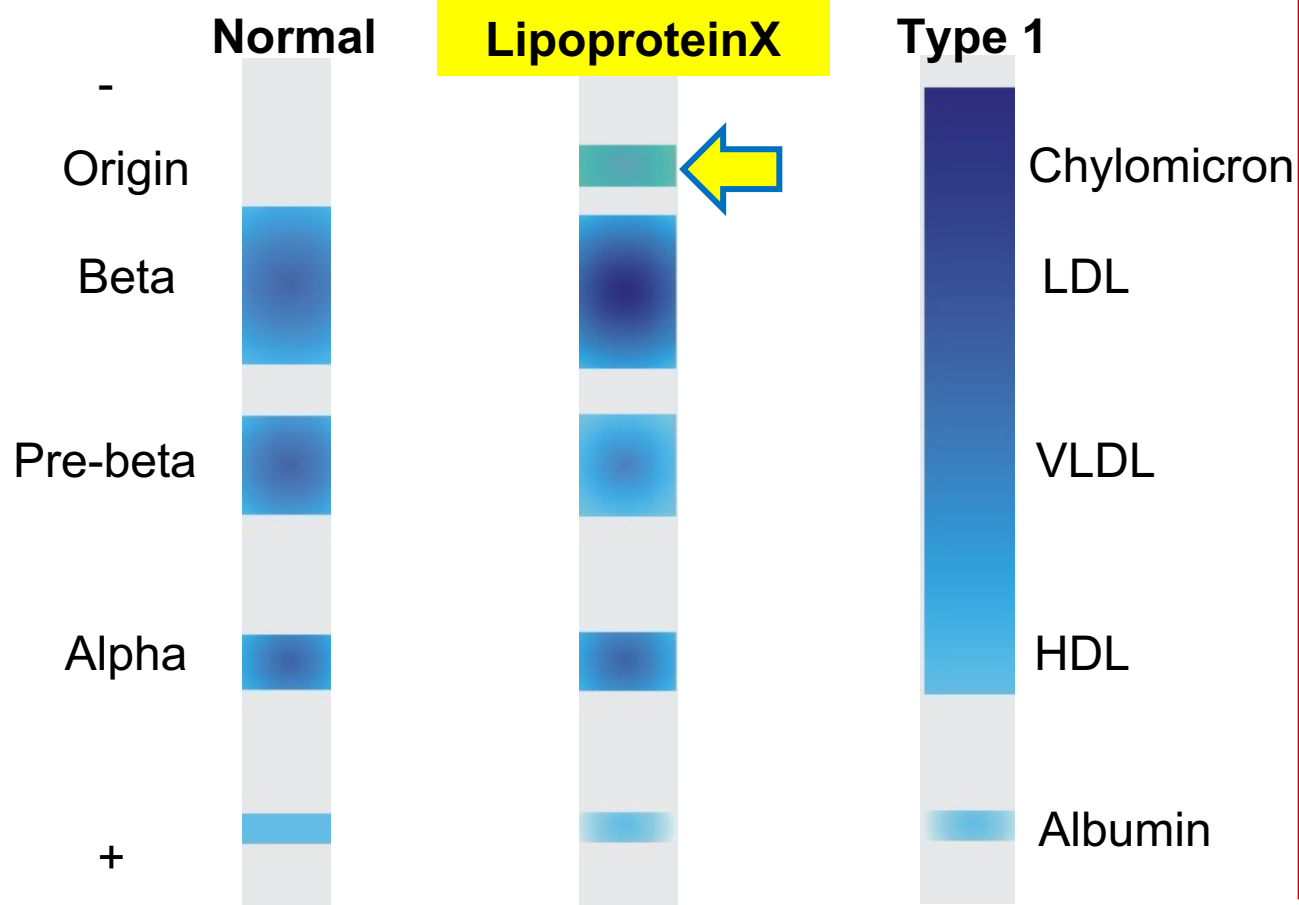

Ophthalmic manifestations  
in diabetes mellitus are not  
only diabetic retinopathy.

# Spot Diagnosis Case 2

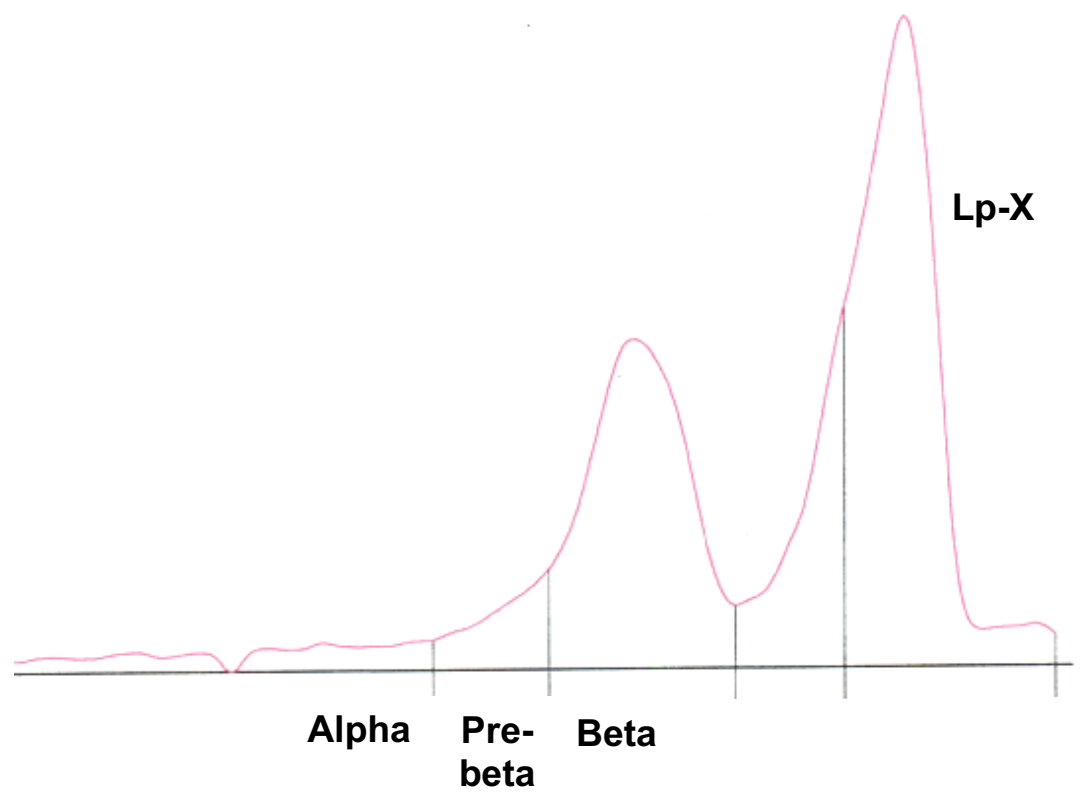
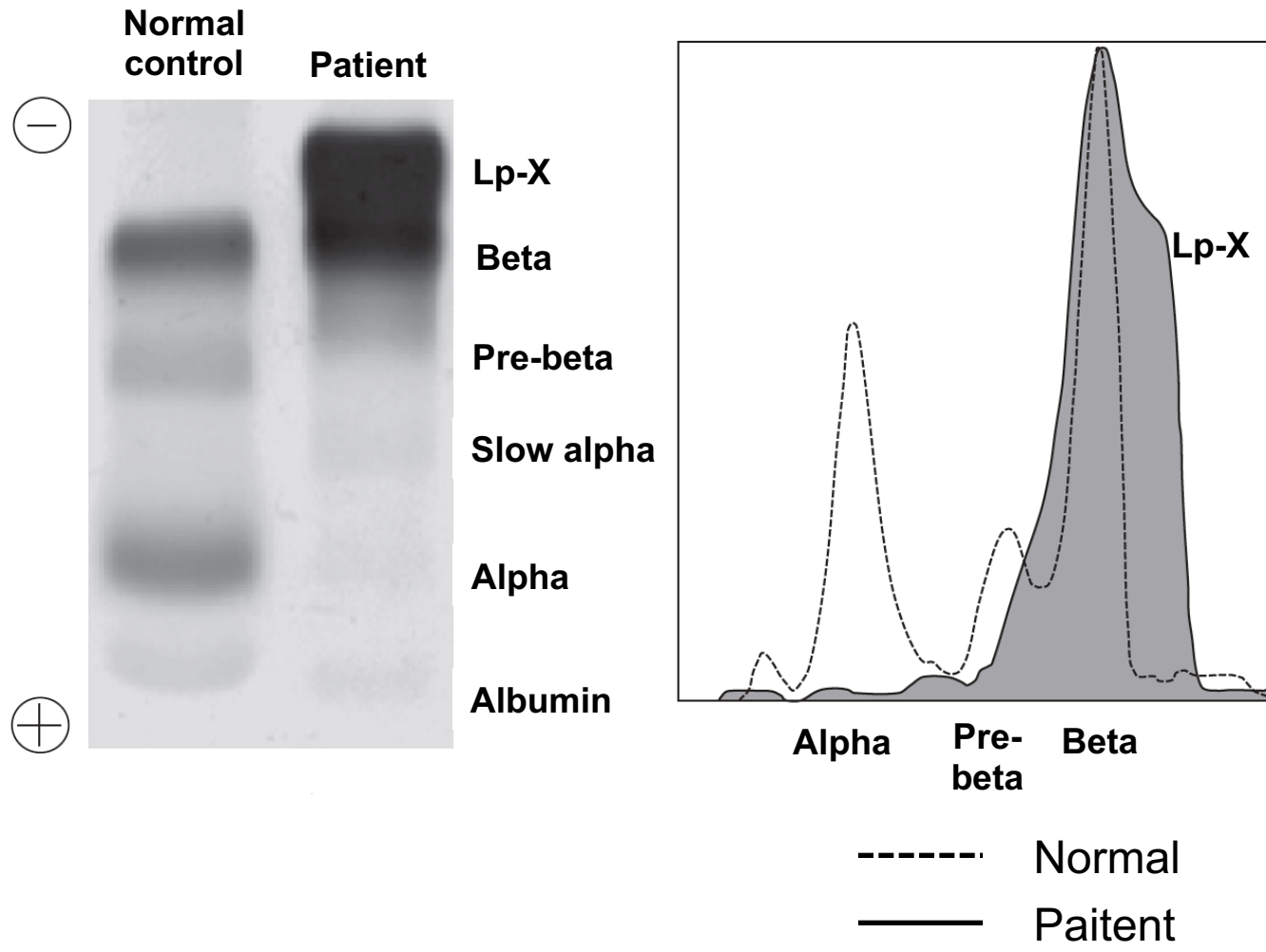
## Lessons Learnt



Admission Day	TC (mg/dL)	TG (mg/dL)	LDL-c (mg/dL)	HDL-c (mg/dL)	TB/DB (mg/dL)	ALP/GGT (U/L)
1	703	259	751	11	6.6/4.6	453/677
3	699	174	776	17	4.5/3.2	386/616



# Our Patient





**Diagnosis:** Acute cholangitis due to CBC stone obstruction

: Lipoprotein x from obstructive liver disease

**Treatment:** Endoscopic Retrograde Cholangiopancreatography (ERCP)

Day	Cholesterol (mg/dL)	TG (mg/dL)	LDL-c (mg/dL)	HDL-c (mg/dL)	TB/DB (mg/dL)	ALP/GGT (U/L)
1	703	259	751	11	6.6/4.6	453/677
3	699	174	776	17	4.5/3.2	386/616
21	346	-	89	-	2.9/2.2	249/228



# Lipoprotein X (LpX)

- » Abnormal lipoprotein with similar density to LDL-c lacking apolipoprotein A and B
- » Causes: cholestasis (1° biliary cirrhosis, 1° sclerosing cholangitis),  
LCAT def, GVHD, pregnancy
- » Originated from intestinal mucosa
- » Normally undetectable in the blood
- » Obstructive jaundice: reflux of biliary lipoprotein into the systemic circulation
- » Do not usually require therapy
- » Anti-atherogenic: ↓LDL oxidation, preserve endothelial homeostasis



# Lipoprotein electrophoresis

N    I    LpX    IIa    IIb    Mod LDL    III    CSD    Lp(a)    IV    V    Ab    hyper<sub>a</sub>    hypo<sub>a</sub>    Aged    heparin



Origin

Beta

Pre-beta

Alpha




Chylo  
micron

LDL

VLDL

HDL

Albu  
min



# Spot Diagnosis Case 3

## Lessons Learnt



# Osteoporosis during pregnancy and lactation

- » The mechanisms of pregnancy-related osteoporosis is also unclear
- » BMD increased spontaneously by a mean of 10% after weaning
- » Traditional management of postpartum osteoporosis includes:
  - Advised against breast-feeding and supportive treatment
  - Vitamin D (800 IU/day) and calcium (1200mg/day)
  - Nasal calcitonin, Bisphosphonates, Strontium ranelate, Teriparatide → Lack of controls trial, BMD might spontaneously increased
- » There is no clear evidence to link osteoporosis during pregnancy and lactation with postmenopausal osteoporosis and fracture